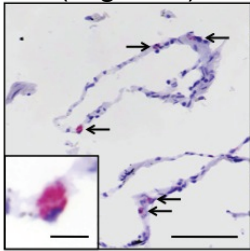
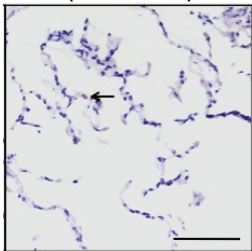


Low emphysema
(Low Lm)

High emphysema
(High Lm)

Alveolar
Tissue



Small
Airway
Wall

