




Distal articular surface



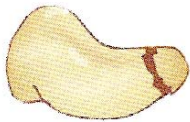
Distal tubercle



Distal third



Middle third



Proximal third