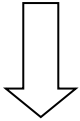


Treatment of ASBO

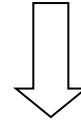
- No signs of strangulation or peritonitis
- Surgery more than 6 weeks before ASBO
- Partial ASBO
- Signs of resolution on admission



Non operative management:

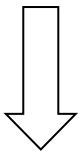
- NGT or LT decompression
- Intravenous fluid administration
- Clinical observation

- Signs of strangulation or peritonitis
- Surgery within 6 weeks before ASBO
- Carcinomatosis or irreducible hernia
- No signs of resolution within 72h



Operative management:


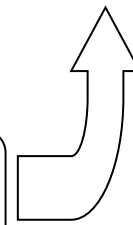
- Laparoscopic exploration
- Open approach



Water Soluble Contrast Medium Administration



No contrast in the colon within 24-36 hrs



Appearance of contrast in the colon within 24h predicts RESOLUTION OF ASBO

Further indications for delayed operation:

- Evolving peritoneal signs
- Persistent ileus >72h
- Drainage volume >500ml on 3rd day
- Pain lasting 4 days or more
- CRP \geq 75 mg/l
- WBC \geq 10.000/mm³
- Free intraperitoneal fluid \geq 500ml on CT
- Reduction of CT small bowel wall contrast enhancement