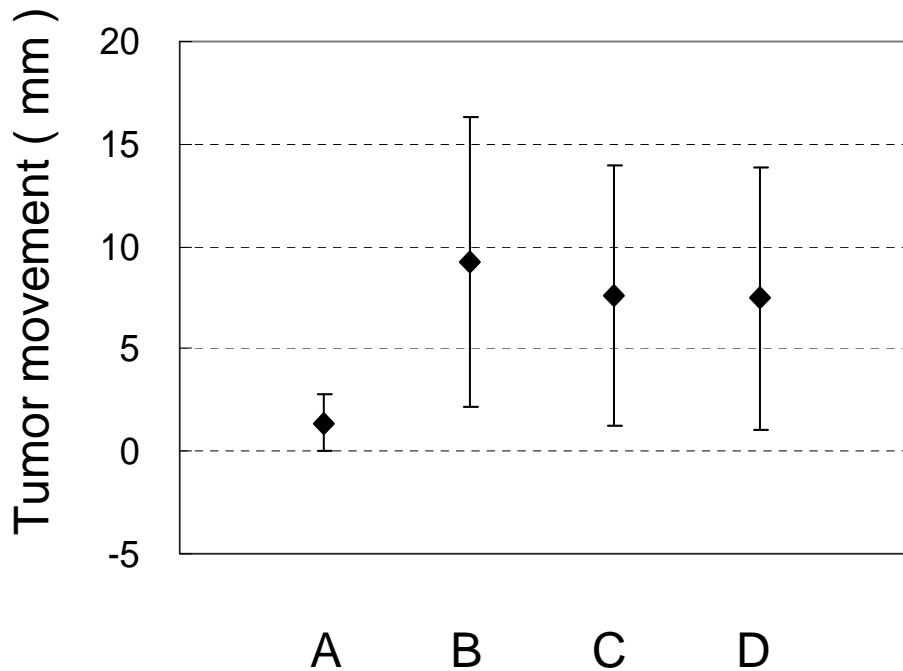
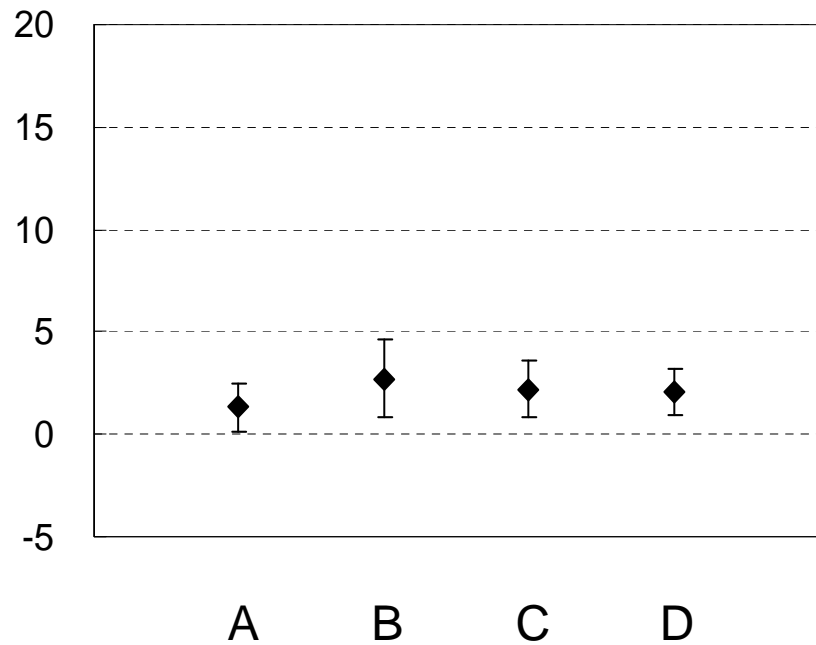


Craniocaudal direction



Right-to-left direction



Patient condition