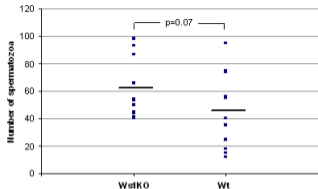
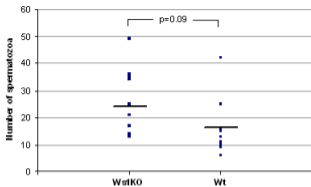


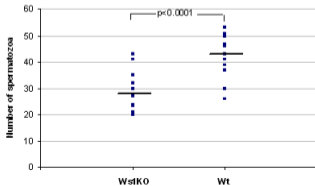
a) light-type cytoplasmic droplets



2) heavy-type cytoplasmic droplets



c) proximal bent tails



d) abnormal sperm heads

